

compare well. The table shows the results in the various dietary groups.

EXPERIMENTAL RESULTS

Acute and chronic scurvy were effective in producing lesions of the arterial intima indistinguishable from the lesions which have been described in early human atherosclerosis.⁹ These lesions developed in as little as 15 days from the onset of the scorbutic diet. This represents a very short time when it is recalled that it takes about 12 days to produce ascorbic acid depletion in the guinea pig.¹⁴ The lesions occurred at normal cholesterol levels and were unaccompanied by lipid deposits in the spleen.

Cholesterol feeding resulted in similar lesions with approximately the same rapidity but with hypercholesterolaemia and lipid deposits in the spleen. The combination of scurvy and cholesterol feeding was the most potent method of producing atherosclerosis, being effective in all the animals in which it was tried. Intraperitoneal ascorbic acid prevented the production of atherosclerosis of cholesterol feeding in 11 of 18 animals and the lesions in the remaining 7 were of minimum degree. None of the 38 control animals had atherosclerosis.

Fig. 1 shows a typical atherosclerotic lesion in a scorbutic guinea pig without cholesterol feeding.

COMPLICATIONS OF THE GROUND SUBSTANCE

DISTURBANCE IN ATHEROSCLEROSIS

Once the lipid has been deposited in the altered ground substance certain other processes begin.

Intimal hæmorrhage.—Normally the intima receives its nourishment by diffusion from the arterial lumen and from the vasa vasorum which penetrate into the outer two-thirds of the media.¹⁷ In atherosclerosis, dilated capillaries invade the intima from the vasa vasorum¹⁸ and sometimes directly from the main arterial lumen.¹⁹ These capillaries frequently rupture and produce intimal hæmorrhage.

In a recent study of intimal hæmorrhage in the lower limb arteries of 152 routine autopsies⁵ the phenomenon was present 157 times in 55 of 123 cases exhibiting grossly visible atherosclerosis of these arteries. It was twice as common in men as in women, and was usually associated with hypertension and old age.

Intimal hæmorrhage may occlude the artery by its bulk²⁰ or by precipitating thrombosis.²¹ It

enlarges the plaque in which it occurs and probably propagates the deposition of lipid through a mechanism of further injury.⁸ The following factors contribute to rupture of intimal capillaries:

1. The ectatic nature of these capillaries produces a high tension in their walls as calculated by Laplace's law.

2. The inter-endothelial cement of these capillaries is altered in a way similar to the alteration of the ground substance of the atherosclerotic plaque which they invade. They rupture like capillaries in scurvy.

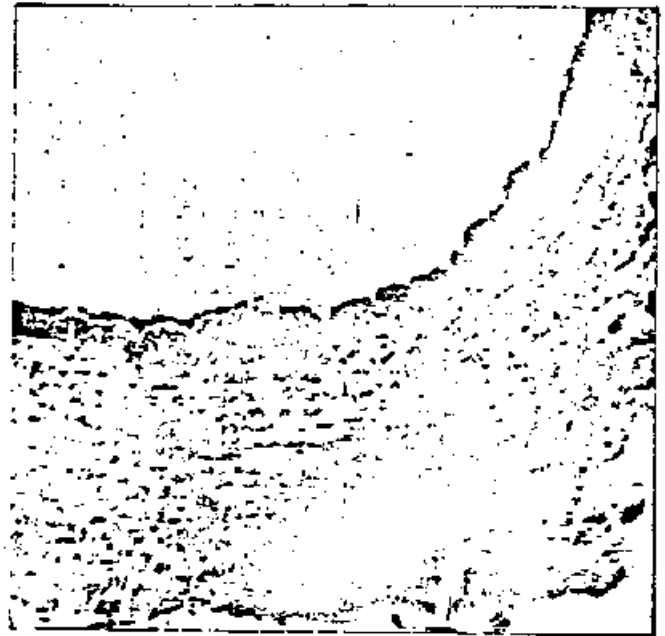


Fig. 1.—Aorta of a guinea pig fed the acute scorbutic diet alone. Note the deposit of stainable lipid filling the intima. This lesion occurred at a normal plasma cholesterol level and was unaccompanied by lipid deposit in the spleen. (Scharlach E.)

3. Those capillaries arising directly from the arterial lumen are exposed to high pressures.

Calcification.—Altered ground substance forms a medium which often calcifies.²²

Thrombosis.—Chambers and Zweifach²³ demonstrated that injury to vascular endothelium results in the development of a stickiness of the inter-endothelial cement. Samuels and Webster²⁴ showed that platelets adhere along the lines of inter-endothelial cement when a vessel is injured. From this beginning, a thrombus is formed. In scurvy thrombus formation is common.¹⁴ Aschoff and Koch²⁵ observed thrombosis of large veins in 33% of their autopsied cases of scurvy, and thrombosis of arteries has been reported in malnutrition.²⁰ It seems likely that the frequency of thrombosis in atherosclerosis is related to the altered ground substance of the intima and its endothelial lining.